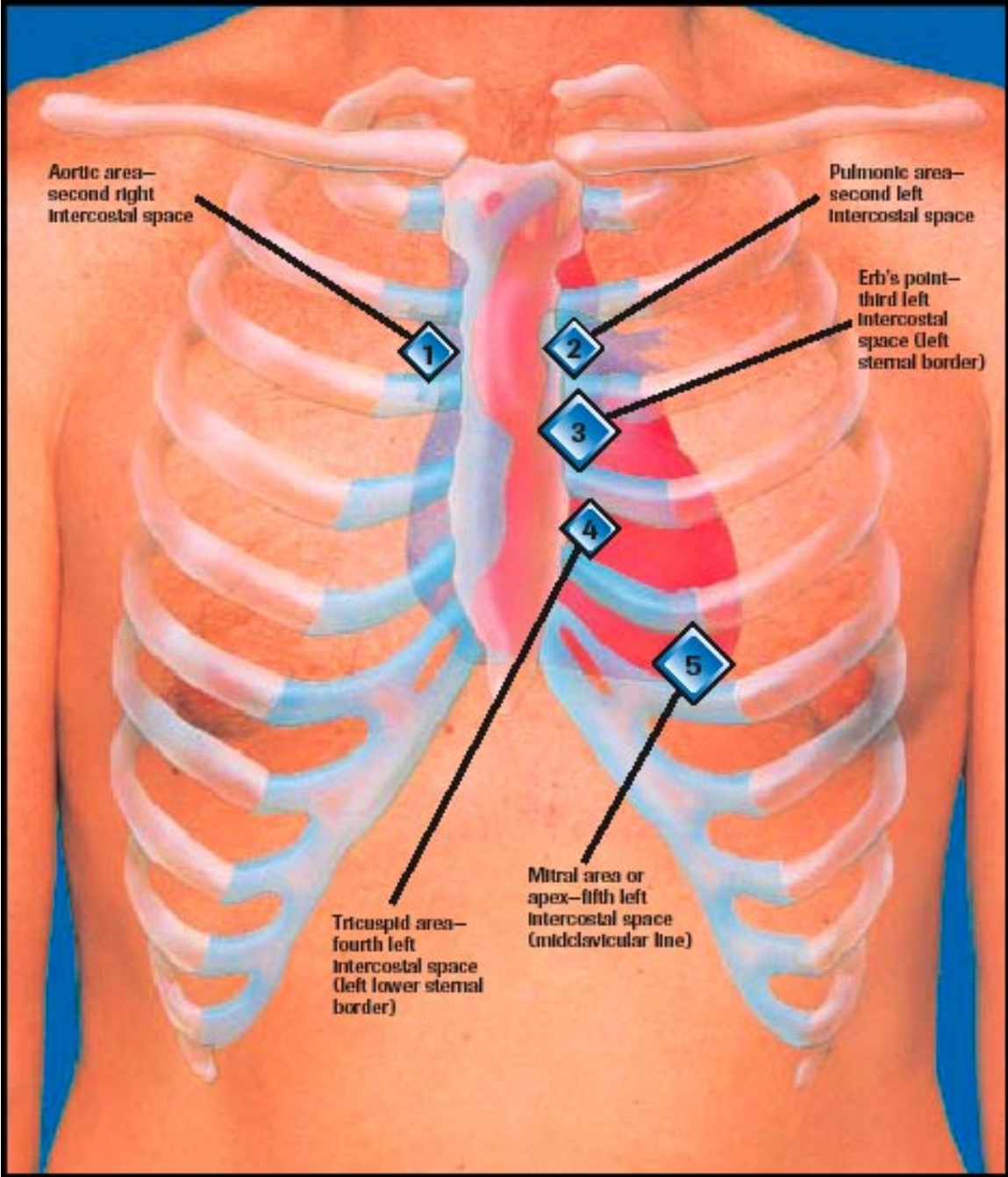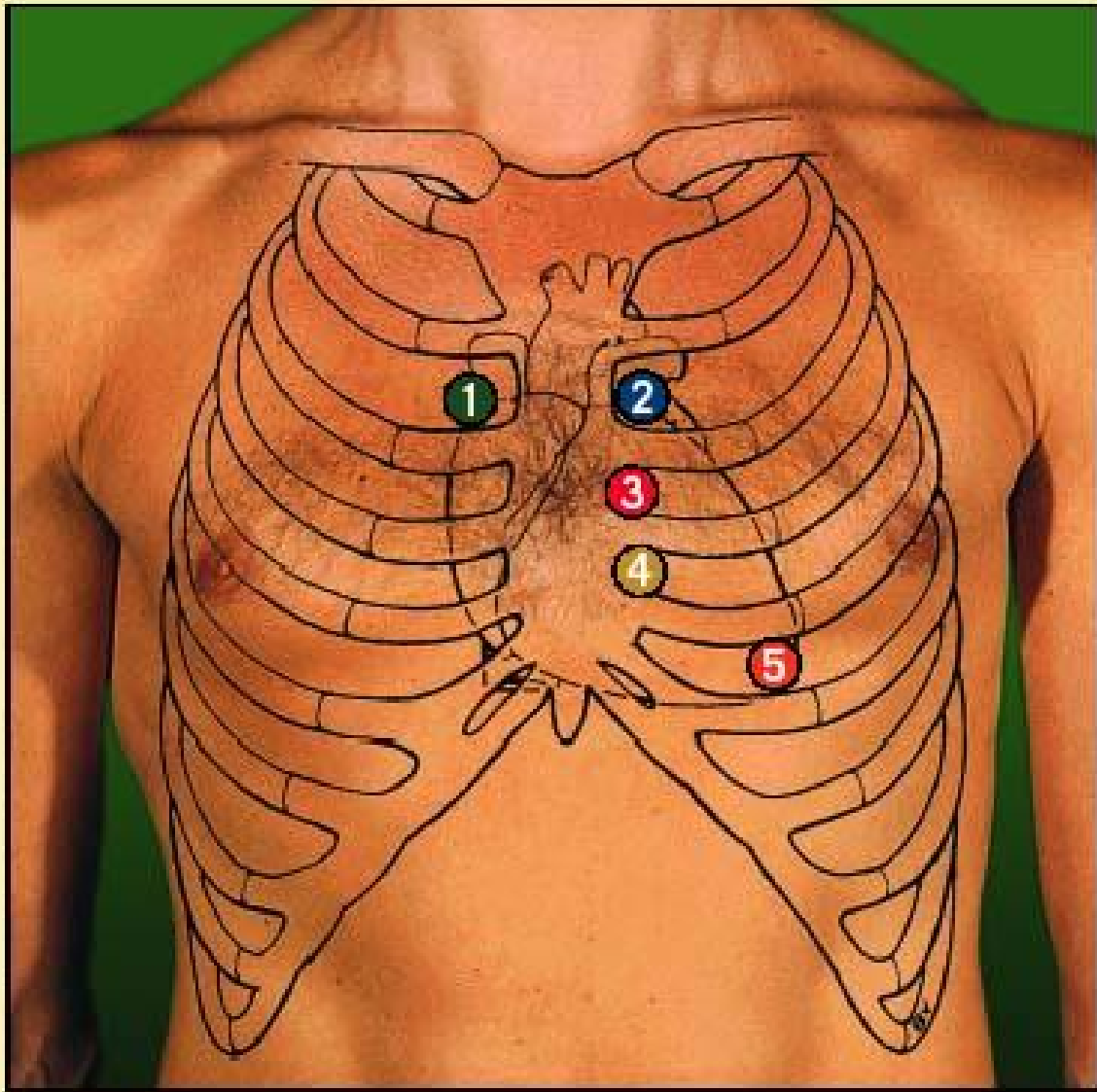


## Locating the assessment points



- 1 Aortic area—second intercostal space, right sternal border
- 2 Pulmonic area—second intercostal space, left sternal border
- 3 Erb's point—third intercostal space, left sternal border
- 4 Tricuspid area—fourth (or fifth) intercostal space, left sternal border
- 5 Mitral area or apex—fifth intercostal space, left midclavicular line